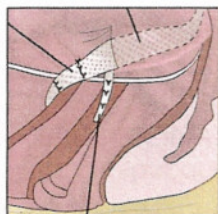


# LAPAROSCOPIC SACRALCOLPOPEXY AND ENTEROCELE REPAIR WITH MESH



***Robert D. Moore, D.D.***

***John R. Miklos, M.D.***

## INTRODUCTION

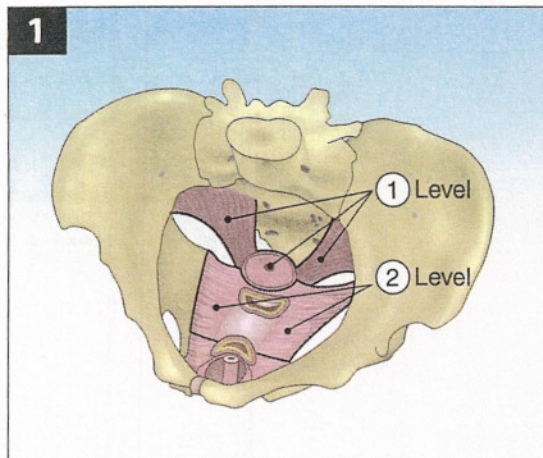
**T**he anatomy, pathophysiology, and treatment of pelvic organ prolapse has significantly evolved over the last decade with increasing understanding of anatomy and development of minimally invasive surgical procedures. Although support for the pelvic viscera, the vagina, and neighboring structures involves a complex interplay between muscles, fascia, nerve supply, and appropriate anatomic orientation, the endopelvic fascia and pelvic floor muscles provide most of the support function in the female pelvis. Laparoscopic reconstructive pelvic surgery requires a thorough knowledge of pelvic floor anatomy and its supportive components before repair of defective anatomy is attempted. This chapter reviews the anatomy and laparoscopic repair of vaginal vault prolapse and enterocele with Y-mesh sacralcolpopexy.

## ANATOMY OF PELVIC SUPPORT

### ENDOPELVIC FASCIA

To understand the pelvic support system of the female pelvic organs, it is useful to subdivide the pelvic support system into 3 axes: 1) the upper vertical axis, 2) the midhorizontal axis, and 3) the lower vertical axis. The endopelvic fascia—a network of connective tissue and smooth muscle—constitutes the physical matrix which envelops the pelvic viscera and maintains the integrity of the axes supporting the bladder, urethra, uterus, vagina, and rectum in their respective anatomic relationships.

DeLancey further describes the 3 levels of support axes as follows: level 1 - superior suspension of the vagina to the cardinal-uterosacral complex; level 2 - lateral attachment of the upper 2/3 of the vagina; and level 3 - distal fusion of the vagina into the urogenital diaphragm and perineal body. Level 1-paracolpium suspends the vaginal apex from the lateral pelvic sidewall via the uterosacral-cardinal complex. Level 2-the anterior vaginal wall is attached laterally to arcus tendineus fascia pelvis and the posterior vaginal wall is attached laterally to the fascia overlying the levator ani muscle. In this support system, the endopelvic fascia system is thought to be continuous, extending from the origin of the cardinal-uterosacral complex to the urogenital diaphragm, providing structural support to the vagina and adjacent organs (Figure 1). In this chapter we will be concentrating on Level 1 or apical support.



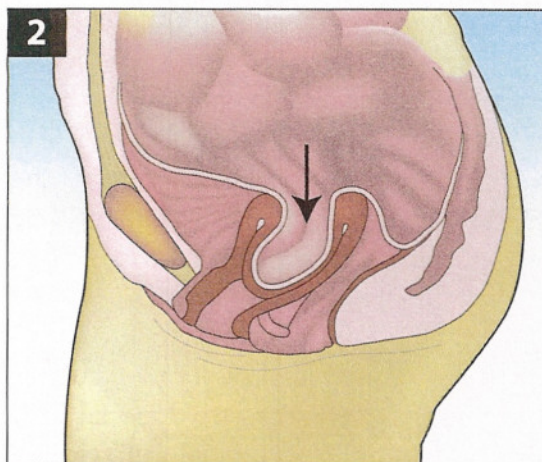
### LEVEL 1 – APICAL SUPPORT

The cardinal-uterosacral complex provides apical support by suspending the uterus and upper one third of the vagina to the bony sacrum. This complex can be described as two separate entities: the cardinal ligament and the uterosacral ligament. The cardinal ligament is a fascial sheath of collagen that envelops the internal iliac vessels and then continues along the uterine artery, merging into the visceral capsule of the cervix, lower uterine segment and upper vagina. The uterosacral ligament is denser and more prominent than the cardinal ligament. Collagen fibers of the uterosacral ligament fuse distally with the visceral fascia over the cervix, lower uterine segment, and upper vagina, forming the paracervical ring; proximally these fibers end at the presacral fascia overlying the second, third, and fourth sacral vertebrae. This complex appears to be the most supportive structure of the uterus and upper 1/3 of the vagina. Disruption of the car-



dinal-uterosacral complex may result in uterine descensus or vaginal vault (apex) prolapse. Likewise, the most common cause of vaginal vault prolapse is previous hysterectomy with failure to adequately reattach the cardinal-uterosacral complex to the pubocervical fascia and rectovaginal fascia at the vaginal cuff, intraoperatively.

An enterocele is defined as a pelvic floor hernia where the parietal peritoneum comes into direct contact with the vaginal epithelium with no intervening fascia. In normal pelvic supportive anatomy, the anterior pubocervical fascia, posterior rectovaginal fascia, cardinal-uterosacral ligaments and paracolpial fibers all converge, or fuse to form the pericervical ring. The integrity and continuity of these supportive tissues can be compromised in patients who have had a complete hysterectomy as previously described. An enterocele is likely to be directly related to a disruption of the fusion of the proximal margins of the pubocervical and rectovaginal fascia (Figure 2). Although vaginal mucosa may cover this defect, it is not supportive, which greatly increases the likelihood that an enterocele will eventually develop within the vaginal cavity. Though it is possible to have an enterocele without concurrent vaginal vault prolapse, the two defects usually occur concomitantly. Although the depth and overall anatomic configuration of the cul-de-sac have been implicated in the development of the enterocele, it has never been proven to be the primary etiology.



## **LEVEL I SUPPORT - LAPAROSCOPIC APPROACH TO ENTEROCELE REPAIR AND VAGINAL VAULT SUSPENSION**

### **SITE-SPECIFIC ENTEROCELE REPAIR & VAGINAL VAULT SUSPENSION**

As previously mentioned, level 1 support involves the long paracolpial fibers which suspend the proximal vagina and cervicovaginal junction. The cardinal and uterosacral ligaments previously described merge with these fibers and attach to the pericervical ring. This network of connective tissue fibers and smooth muscle serves to prevent vaginal eversion. A disruption of the integrity of these fibers, as opposed to stretching, results in apical vaginal vault eversion. A disruption of the fascia at the vaginal cuff results in an enterocele formation.

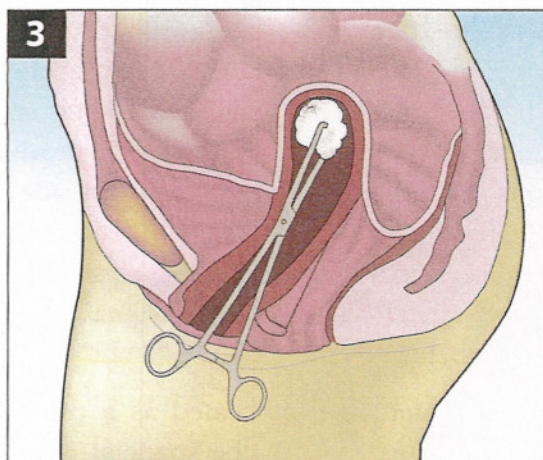
Enterocele repair begins first by anatomically defining the fascia defect present that results in the herniation of



peritoneum and bowel through the apex of the vagina. An enterocele is defined as a pelvic hernia where the parietal peritoneum comes into direct contact with vaginal epithelium with no intervening fascia. The development of an enterocele is likely to be directly related to a disruption of the fusion of the proximal margins of the anterior pubocervical fascia and posterior rectovaginal fascia or failure to surgically reattach these two fascial margins at the time of vaginal cuff closure following hysterectomy. It is possible that the surgeon may not incorporate the apex of the pubocervical and or the rectovaginal fascia at the time of closure of the vaginal cuff. Instead the surgeon may be only incorporating vaginal mucosa and unintentionally neglecting the reattachment of the supportive fascial layers. Poor surgical closure or disruption at the apex of the pubocervical and rectovaginal fascia results in parietal peritoneum in direct contact with vaginal epithelium. Chronic rises of intraabdominal pressure will ultimately exploit this vaginal weakness with stretching of the peritoneum and vaginal mucosa and clinically evident symptomatic enterocele.

### LAPAROSCOPIC ENTEROCELE REPAIR

The technique of laparoscopic enterocele repair begins with identification of the vaginal vault apex, the proximal uterosacral ligaments and the course of the pelvic ureter. The identification of the vaginal vault and the delineation of the rectovaginal and pubocervical fascia are facilitated by the use of a vaginal probe. Using the vaginal probe (Figure 3), trac-



tion is placed cephalad and ventrally, causing the uterosacral ligaments to stretch so they can be identified and traced backward to their most proximal point of origin, lateral to the sacrum. In many cases the uterosacral ligaments are of very poor quality and/or very stretched out. Therefore, we believe that the utilization of mesh to suspend the apex and ultimately assist in enterocele repair shows superior cure rates compared to utilizing ligaments that have already failed. An apical enterocele is often encountered with vault prolapse. The vault is elevated up into the pelvis with an EEA sizer and the excess vaginal epithelium is identified (Figure 4).

The peritoneum overlying the vaginal apex is incised to expose the pubocervical fascia anteriorly and the rectovaginal fascia posteriorly. If the edge of the bladder is difficult to identify, the bladder is retrograde filled with sterile water to help identify the edge and then the bladder is dissected off of the anterior apical portion of the vagina. Likewise if the recto-

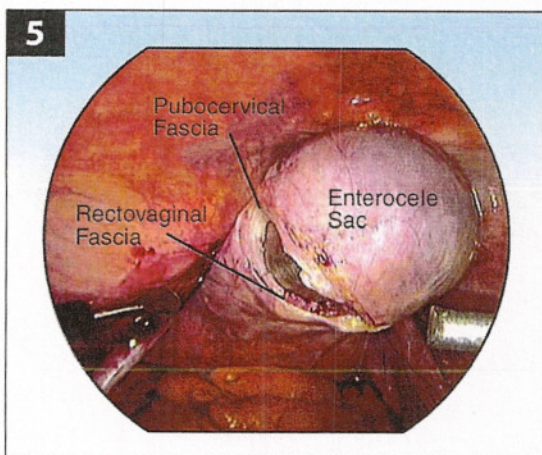
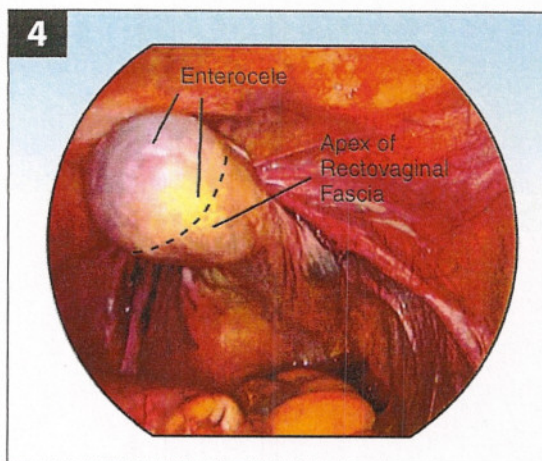


vaginal space is difficult to identify, a rectal probe can be placed to identify the rectum and the peritoneum incised between the rectum and the vagina. The rectovaginal space can then be identified and the rectum dissected off the posterior wall of the vagina, almost all the way down to the perineal body. If the enterocele sac is large, it may be excised and the apical edges of the pubocervical and rectovaginal fascia should be exposed (Figure 5). The excess vaginal epithelium is excised to get down to the level of the pubocervical fascia anteriorly and the rectovaginal septum posteriorly. The cuff is then reapproximated with interrupted sutures. If the enterocele sac is smaller, the pubocervical fascia and rectovaginal septum can be reapproximated at the apex with plication sutures, therefore avoiding excision.

The enterocele repair is further supported by the placement of the Y-mesh over the apex of the vagina, as the anterior leaf goes approximately 1/3 of the way down the anterior vaginal wall and the posterior leaf, approximately 2/3 of the way down the posterior wall (ensuring attachment of the mesh to the pubocervical fascia anteriorly) and the rectovaginal fascia posterior.

## LAPAROSCOPIC SACRAL COLPOPEXY

Abdominal sacral colpopexy remains one of the most successful operations for the treatment of vaginal vault prolapse with excellent results on long-term follow-up. If the surgeon utilizes laparoscopy as a means of surgical access and performs



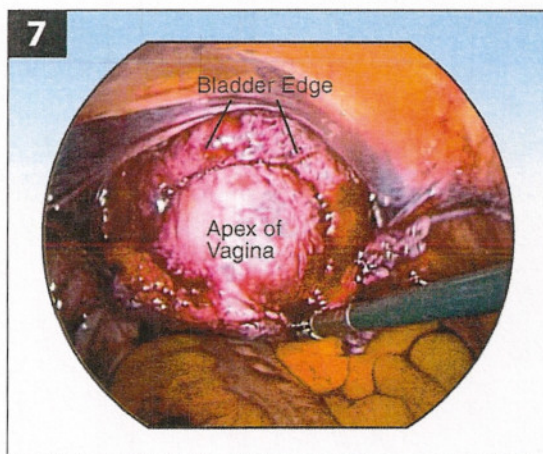
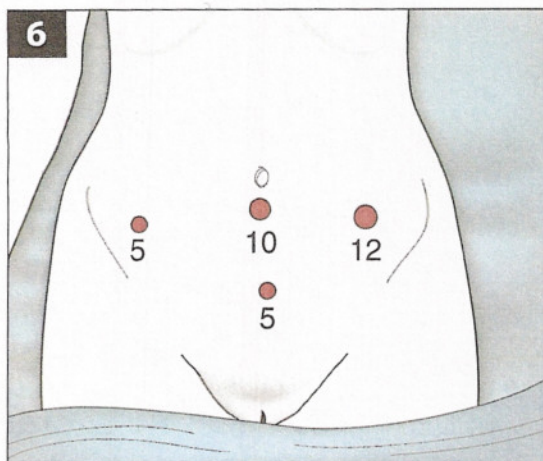
the sacral colpopexy in the same manner as in the open abdominal approach, operative cure rate should theoretically be equivalent.

The room set-up and patient positioning are exactly the same as we described in the Laparoscopic Paravaginal Repair and Burch Urethropexy chapter. The patient is placed in dorsal lithotomy position with adjustable Allen stirrups. A 3-way 16-Fr Foley catheter is placed for gravity drainage. Inflatable sequential



compression devices are placed on the patient's lower extremities for DVT prophylaxis. A 48-hour bowel prep is used for all of our laparoscopic patients. This helps decompress the bowel for better visualization and helps minimize risk of infection if bowel injury occurs. Two days prior to surgery the patient is placed on a full liquid diet (shakes, pudding, etc.), and the day prior to surgery only clear liquids are allowed. The afternoon prior to surgery the patient drinks 8 ounces of magnesium citrate to clean out the bowels. We also do not recommend the use of nitrous oxide for an anesthetic agent during laparoscopy because this can cause bowel distention during the case and increase risk of bowel injury.

Port placement is based on the surgeon's preference, skill and acquired technique. We place our ports in an identical fashion as was described in the Laparoscopic Paravaginal Repair and Burch Urethropexy chapter. Briefly, we utilize a 10 mm suturing port in the left paramedian region, and two 5 mm ports, one in the suprapubic region and the other in the right paramedian region (Figure 6). The surgeon stands on the patient's left side and completes all needle passing, suturing, needle retrieving and knot tying by himself utilizing the left paramedian and suprapubic port. The assistant stands on the patient's right side and drives the camera and utilizes the right lower port for retraction, suction/irrigation, etc. Once the operative ports have been placed, the vagina is elevated with an EEA sizer and the peritoneum overlying the vaginal apex is dissected posteri-

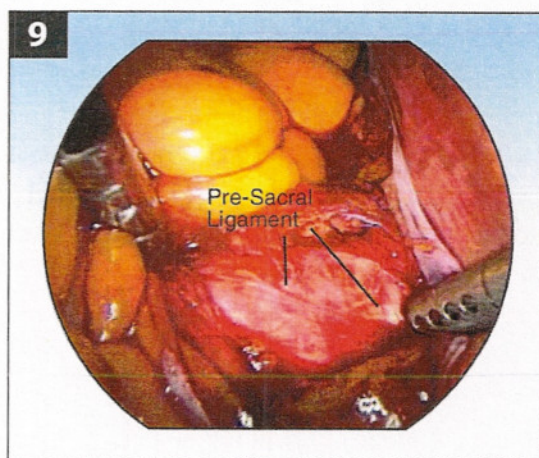
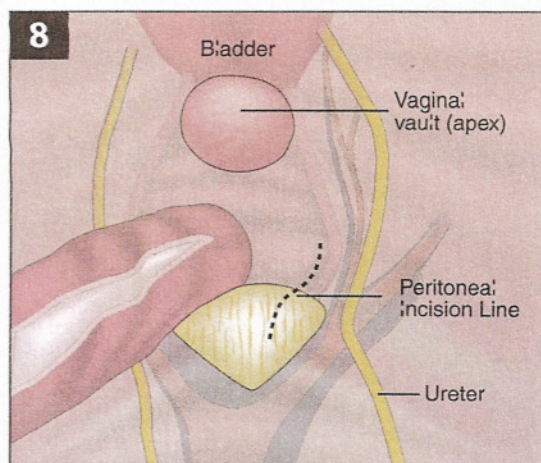


only exposing the apex of the rectovaginal fascia. This dissection opens the rectovaginal space as described above and the dissection is taken down to within 3 cm of the perineal body (Figure 7). Any bleeding can be controlled with bipolar electrocautery or surgical clips. Next, anterior dissection is performed to delineate the apex of the pubocervical fascia by dissecting the bladder off of the anterior apex of the vagina. If the edge of the bladder is difficult to identify secondary to scar tissue, the bladder can be retro-



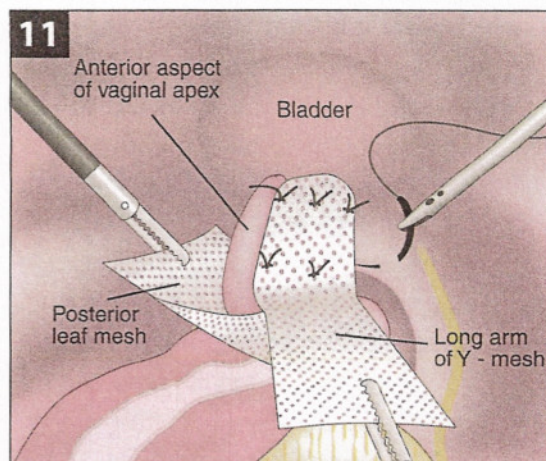

grade filled through the 3-way Foley catheter with sterile water and then the bladder can be carefully dissected off the anterior segment. We take this dissection approximately 1/3 to 1/2 way down the anterior wall. A separation between the rectovaginal and pubocervical fascia confirms an enterocele at the apex. If a small enterocele is present it should be repaired in a site-specific fashion by imbricating the stretched vaginal epithelium between the apical edges of the pubocervical and rectovaginal fascia. Permanent suture can be utilized in a continuous purse-string fashion or in interrupted fashion. A large enterocele should be resected (as shown in Figure 5) and the cuff reapproximated with absorbable sutures so the excessive vaginal epithelium is not utilized as a point of mesh attachment. Theoretically, suturing the mesh to the enterocele sac, instead of the more supportive pubocervical and rectovaginal fascia, may predispose the patient to an increased risk of mesh erosion, suture pullout and/or surgical failure.

Attention is then directed to the sacral promontory and the presacral space. The peritoneum overlying the sacral promontory is incised longitudinally and this peritoneal incision is extended to the cul-de-sac (Figure 8). A laparoscopic dissector is used to expose the anterior ligament of the sacral promontory through blunt dissection (Figure 9). The peritoneum on the sidewall is incised and freed up beneath the ureter so that the mesh can be retroperitonealized at the end of the case. Hemostasis is achieved using either coagulation or surgical clips.

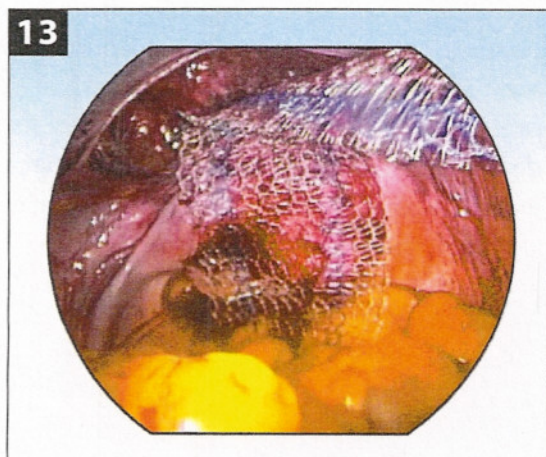
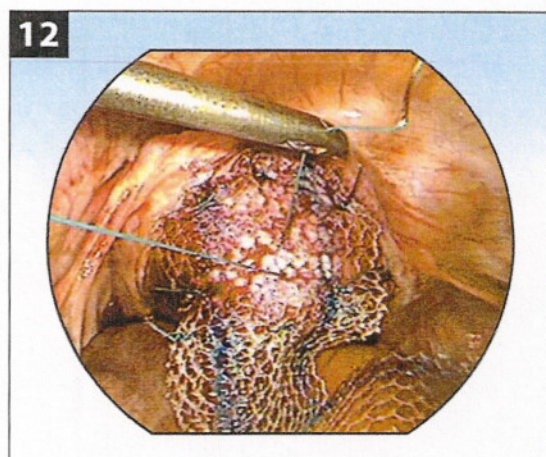


A 12 cm X 4 cm polypropylene mesh graft is fashioned into a Y shape, so there is an anterior and posterior leaf of the mesh. Typically the anterior leaf is about 3-4 cm long and the posterior leaf is longer at 5-6 cm so that it can be brought down deeper into the rectovaginal space (Figure 10). The mesh is then introduced into the abdominal cavity through a 10-or 12 cm port. The posterior leaf is sutured back to the tail of the mesh to keep it out of the way, as we suture the anterior leaf in place first. The vaginal apex is then



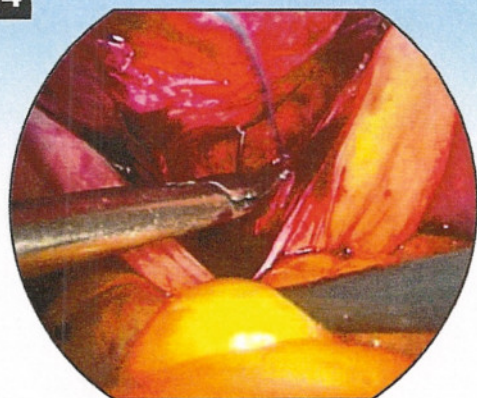


directed anterior and cephalad exposing the pubocervical fascia for application of the surgical graft. The anterior leaf of the mesh is then sutured to the pubocervical fascia with three pairs of no. 2-0 nonabsorbable sutures beginning distally and working towards the rectovaginal fascia apex (Figures 11, 12). We utilize nonabsorbable sutures and tie extracorporeally with a closed loop knot pusher, which is time saving and efficient. All suturing methods and equipment are described in detail in the Laparoscopic Paravaginal Repair and Burch chapter. We utilize the same techniques for suturing with enterocele repair and sacralcolpopexy. The first suture is placed through the mesh and then through the pubocervical fascia, being careful to avoid the bladder edge. Once the anterior leaf is sutured in place, the posterior leaf is then released and sutured in place in a similar fashion (Figure 13). We typically place the most distal suture through the vagina first (being careful to avoid the rectum) and then bring the suture

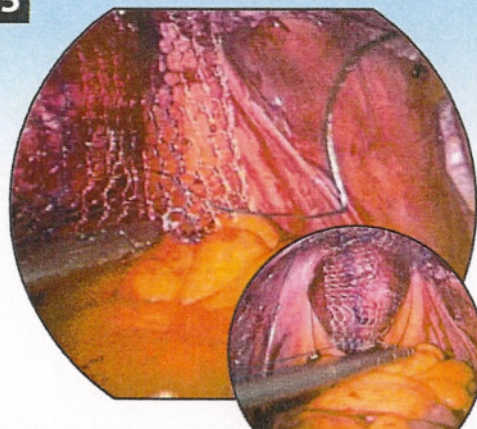




14

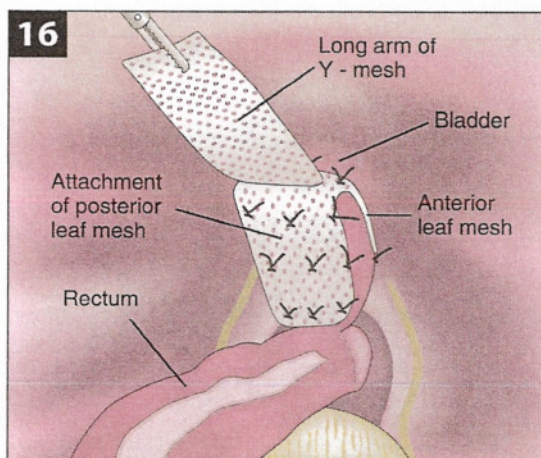


15

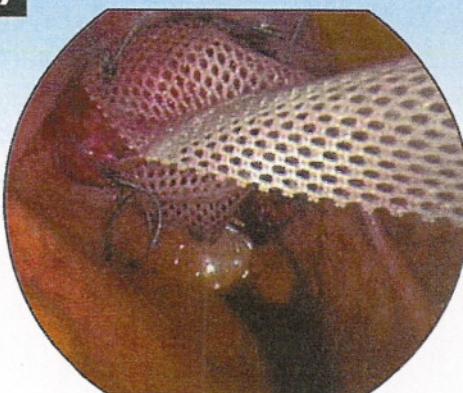


through the mesh and then tie it down into position. The vagina is tented up in the pelvis and the most distal suture (approximately 2/3 down the posterior wall) is placed through the posterior wall (Figure 14), fed through the mesh and then subsequently tied down with an extracorporeal closed-loop knot pusher (Figure 15). Hooked scissors are used throughout the case as they can easily “hook” the suture and slide down to the point it needs to be cut. This helps protect surrounding visceral structures, by pulling the suture away from them prior to cutting the suture. The remaining sutures are taken through the mesh and the vagina, typically in one bite. The posterior leaf is attached with 6-8 sutures as it is longer than the anterior leaf. The final Y-shaped configuration is seen in Figures 16 and 17. This helps repair and prevent further enterocele formation at the cuff in addition to supporting the apex after attachment to the sacrum. The surgeon should attempt to take stitches through the entire thickness of the vagi-

16



17

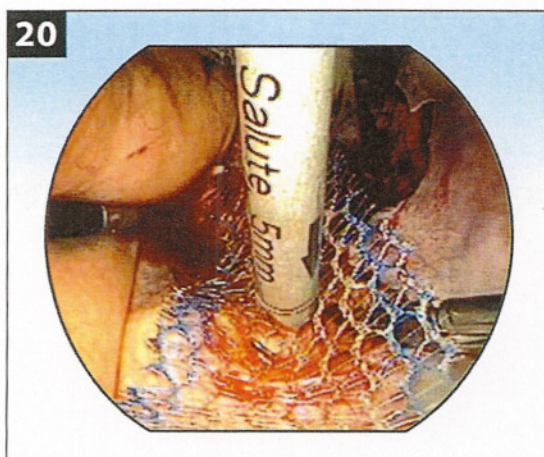
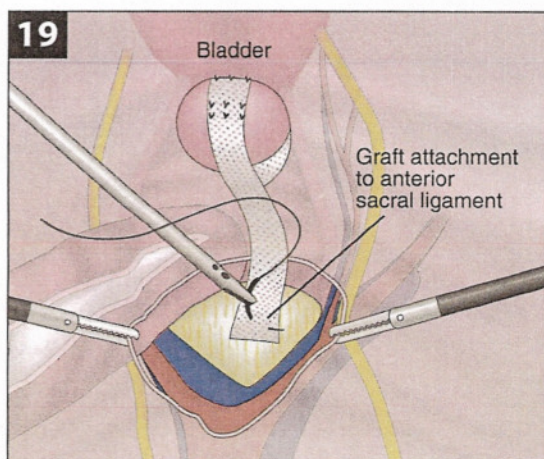
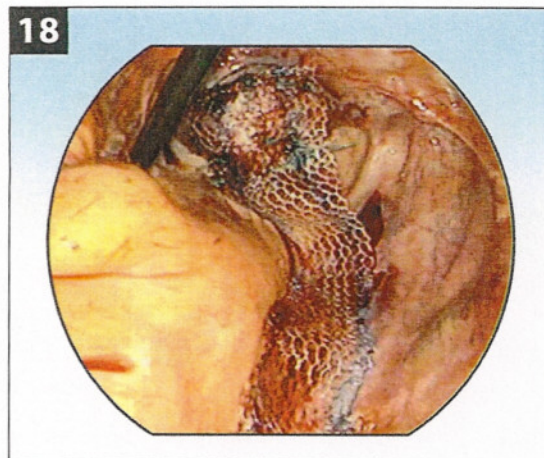




nal wall, excluding the vaginal epithelium. If hysterectomy is completed at the time of the surgery, the cuff is reapproximated in the normal fashion prior to mesh placement and the procedure is then completed in the identical fashion as above. Some have suggested the use of a double-layer closure of the vaginal cuff to help decrease the rate of mesh erosion. However, we do not routinely do this and we have seen no increased rate in cuff erosion. We do feel it is very important, however to keep the sutures that are being placed together to hold the mesh in place away from the vaginal cuff, as suturing the mesh right into the cuff can lead to extrusion in the suture line.

The apex of the vagina is then elevated into its normal anatomic position and the mesh is positioned in the pelvis for its attachment to the pre-sacral ligament. The mesh is positioned so that there is no tension on the vagina (Figure 18).

The surgeon sutures the free end of the Y-shaped mesh to the anterior longitudinal ligament of the sacrum using two pairs of No. 0 nonabsorbable suture (Figure 19). In an attempt to decrease surgical time some surgeons have utilized titanium bone tacks and hernia staplers for the mesh attachment to the anterior longitudinal ligament of the sacrum (Figure 20). After reducing intraabdominal pressure and inspecting the presacral space for hemostasis, the peritoneum is reapproximated with 2-0 polyglactin suture. We utilize a running suture starting at the level of the sacrum, down the sidewall, then up through the bladder





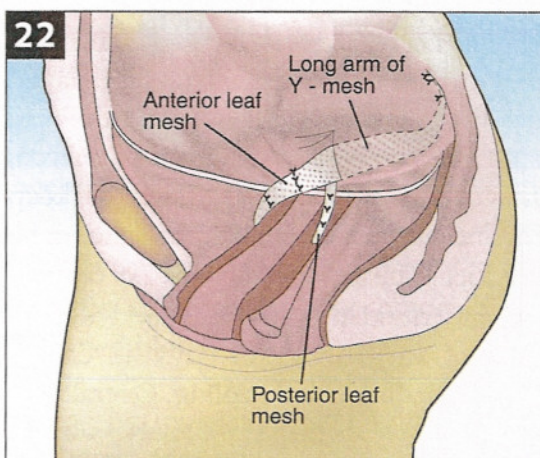
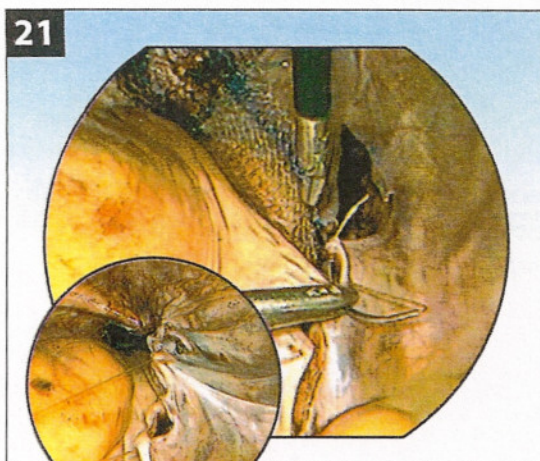
peritoneum, then run it partially back up the sidewall to be able to tie easily near the starting point (Figure 21). Sideview of sacral colpopexy final positioning demonstrates the support of the apex with the graft going down the anterior and posterior walls attached to both pubocervical fascia and rectovaginal septum (Figure 22). We feel the most important aspect of retroperitonealizing the mesh is not necessarily to cover over all the mesh, but is to eliminate the open space between the mesh and the right pelvic sidewall where bowel could potentially become entrapped and obstructed or ischemic.

Once the repair is completed, cystoscopy is performed to ensure ureteral patency and to ensure that there is no suture penetration into the bladder or damage to the bladder from dissection or suture placement.

## POTENTIAL COMPLICATIONS AND INJURIES

### Lower Urinary Tract Injuries

Potential injuries can occur to the ureters and or bladder during the repair. The ureters should be identified at the beginning of the case. Clearly the right ureter is at more risk of injury, secondary to the placement of the mesh on the sacrum on the right side of the colon. The right ureter is identified at the pelvic brim prior to dissection down into the pre-sacral space. As this space is opened and the incision is extended down into the pelvis on the right sidewall, the ureter should be clearly visualized throughout



the dissection and is actually released laterally, away from the operative field with the dissection. The ureters could also potentially be compromised during suture placement of the mesh arms onto the anterior and posterior vagina, specifically the most distal lateral sutures on the anterior wall near the edge of the bladder where the ureters are entering into the bladder (a good dissection will help avoid this danger area) and the lateral sutures of the posterior leaf near the uterosacral ligaments. Cystoscopy is per-



formed at the end of the procedure to ensure ureteral patency. If ureteral obstruction is identified, the suture causing this must be identified and removed and ureteral patency confirmed. If any evidence of compromise or injury is identified to the ureter, a ureteral stent should be left in place for 14-21 days. If a suture is seen penetrating the bladder, it needs to be removed (laparoscopically) and replaced away from the bladder; no further treatment is necessary. If cystotomy occurs during the original dissection of the bladder off of the vagina, this should be repaired laparoscopically with a double-layer closure with delayed absorbable sutures. The procedure can still be completed and mesh placed, however, care should be taken to keep the mesh away from the suture line in the bladder. The bladder should be drained for an extended period of time with this type of an injury (7-10 days) to ensure proper drainage and healing. Overall, the risk of lower urinary tract injury is lower with sacralcolpopexy than with other vault suspensions such as uterosacral ligament suspension.

## BOWEL INJURY

The bowel can be injured with lysis of adhesions or with dissection of the rectum off of the posterior wall of the vagina. A proper 48-hour bowel prep described above is vital to help decrease the risk of bowel injury as this actually deflates the small and large bowel and makes it much easier to get the bowel out of the pelvis and have it stay in the upper abdomen and out of the surgical field.

Additionally, the use of nitrous oxide should be avoided as well as an anesthetic agent as this will cause the bowel to become distended and inflated, increasing the risk of injury. If a small bowel injury occurs, we recommend primary repair laparoscopically. If a proper bowel preparation was conducted, the mesh sacralcolpopexy can be completed, however, antibiotic coverage should be prescribed for one week postoperatively. If the rectum or large bowel is injured during the dissection into the rectovaginal space, primary repair can be accomplished if proper bowel prep was completed, however, we would not recommend mesh be placed following a large bowel injury. Certainly, antibiotic coverage is warranted postoperatively as well.

## VASCULAR INJURIES

As with any advanced pelvic surgical procedure, a thorough knowledge of the pelvic anatomy and vasculature is required prior to attempting laparoscopic sacral colpopexy. The overall risk for bleeding is actually quite low, however if it does occur, it can be a life threatening event. Our average blood loss in over 300 cases over the past 2 years has been less than 75 cc and we have not had to give any blood transfusions for intraoperative bleeding. We feel that the average blood loss for laparoscopic reconstruction is actually much less than with laparotomy secondary to more precise dissection and better visualization. The bleeding encountered with a large abdominal wall incision is likewise eliminated. There is actually



minimal risk of bleeding or major vasculature injury with dissection of the vaginal cuff. This area can be quite vascular, especially down in the rectovaginal space, however, it is typically venous in nature and can be easily controlled with cautery or surgical clips. Certainly, one should always identify and know the location of the ureters prior to any cauterization or clipping. However, dissection into the presacral space has the potential for catastrophic bleeding. We place the patient in deep Trendelenburg position with a left tilt so the bowel can be placed in the upper abdomen and the rectum will fall off to the patient's left side. The right common iliac artery and vein are identified, as is the ureter. The peritoneum is tented up using fine graspers and the peritoneum incised over the sacral promontory. We then carefully dissect down into the presacral space until we reach the pre-sacral ligament and carefully clean this area off with a laparoscopic Kittner until we see the white of the ligament. The middle sacral artery is identified and we ensure that we find a vessel-free area to suture or attach the mesh. One must be careful as, on occasion, the left common iliac vein can traverse this area as well. If bleeding is encountered during the dissection or down in the sacral hollow, it can be life-threatening and rapid conversion to laparotomy needs to be considered. Bipolar electrocautery, surgical clips or hemostatic sutures may be utilized laparoscopically to try to control the bleeding, but again the position of the ureter needs to be identified to ensure it

is away from the surgical field. FloSeal (Cooper Surgical, USA), a thrombin gel agent, may be utilized laparoscopically and has been shown to control both arterial and venous bleeding. We have utilized this material in several incidences with excellent clinical results and have not had to convert any patient to laparotomy to date. If bleeding cannot be controlled, conversion to laparotomy is required and packing/pressure should be placed immediately to control bleeding and restore volume. The patient may require administration of blood products if necessary. Thumb tacks with bone wax have been utilized in the sacral hollow to control bleeding vessels that have retracted into the sacrum and again hemostatic agents such as thrombin gel may be utilized to help obtain hemostasis. If all of the above fails, interventional radiology may be considered for occlusion of the retracted blood vessels.

## LEVEL 1 SUPPORT PROCEDURES - CLINICAL RESULTS

Richardson first described this anatomic defect for enterocele in 1995 in his landmark paper "The anatomic defects in rectocele and enterocele." Since that time, others have described laparoscopic surgical techniques which employ Richardson's anatomic theories in the treatment of enterocele and vaginal apex prolapse. Recently Carter et al reported on 8 patients who underwent the Richardson-Saye laparoscopic vaginal vault suspension and enterocele repair technique with excellent results.



There are no other reports in the literature that evaluate clinical results of the laparoscopic uterosacral ligaments suspensions and/or traditional types of enterocele repairs such as the Halban and Moskowicz procedures. However, some have described their surgical technique and/or complications. Lyons and Winer reviewed the technique and complications in 276 patients who had either a Moskowicz or Halban procedure. The worst complications encountered in this series were port site infections. Koninckx et al emphasized using the CO<sub>2</sub> laser for vaporization of the enterocele sac, followed by uterosacral ligament shortening and suspension of the posterior vaginal wall. A modified Moschowicz procedure with approximation of the posterior vaginal fascia to the anterior wall of the rectum laparoscopically has also been described. Despite the paucity of data regarding long-term cure rates, the uterosacral ligament suspension and site-specific enterocele repair remain a mainstay in many surgeon's armamentarium.

In 1994 Nezhat et al were the first to report a series of 15 patients who underwent laparoscopic sacral colpopexy. They reported an apical vault cure rate of 100% on follow-up ranging from 3 to 40 months. In 1995, Lyons reported 4 laparoscopic sacrospinous fixation and 10 laparoscopic sacral colpopexies. Ross subsequently reported on 19 patients who underwent laparoscopic sacral colpopexy, Burch colposuspension and modified culdeplasty in 1997. The author reported 7 complications including: 3 cystotomies, 2 urinary tract infections, 1

seroma, and 1 inferior epigastric laceration. Despite 2 patients being lost to follow-up, he reported a cure rate of (13/13) 100% for vaginal apex prolapse at 1 year.

Cosson et al reported on their experience of feasibility and short-term complications in 77 patients who had undergone laparoscopic sacral colpopexies. Laparoscopy was actually performed on 83 patients with symptomatic prolapse of the uterus. Six cases required conversion to laparotomy because of technical difficulties. All of the remaining 77 patients underwent laparoscopic sacrocolpopexy. Subtotal hysterectomy was performed in 60 cases. Three patients required reoperations for hematoma or hemorrhage. Mean operative follow-up was 343 days. Three other patients required reoperation, 1 for a third-degree cystocele and 2 for recurrent stress incontinence. The surgeons concluded that sacralcolpopexy is feasible and the operative time, and post-operative complications are related to the surgeon's experience but remain comparable to those noted in laparotomy.

Use of synthetic mesh for the treatment of vaginal vault prolapse has been performed since 1991 at The University of Auvergne, Clermont-Ferrand. More than 250 cases have been performed there laparoscopically with an apical vault cure rate of approximately 92%. Complications are rare with the most common being mesh extrusion (2%) and only in patients who underwent concomitant hysterectomy. Patients who had uterine suspensions or who have not had a concomitant hysterectomy have



not experienced this complication. (Wattiez A, personal communication - International Society of Gynecologic Endoscopy - Berlin 2002). Rozet et al reported on 363 cases of laparoscopic sacralcolpopexy with polyester mesh with mean follow-up of 14.6 months. Cure rate was reported at 96% and complications were minimal including 3 mesh erosions, 1 bowel incarceration, 1 spondylitis, and 2 mesh infections. We have performed more than 300 laparoscopic Y-mesh sacralcolpopexies with macroporous soft polypropylene mesh in the past 2 years and have had excellent clinical results with a very low rate of complications. Our cure rate is greater than 94% and we have had only 2 mesh erosions (0.6%) to date and both patients underwent concomitant hysterectomy.

## CONCLUSION

Laparoscopy should only be considered a mode of surgical access, which should not significantly change the technique of operative reconstructive surgery. Laparoscopy benefits the surgeon by improving visualization, decreasing blood loss and magnifying the pelvic floor defects which need to be repaired.

Other advantages including less postoperative pain, shorter hospital stays, shorter recovery time and earlier return to a better quality of life have also been described in the literature. Disadvantages often cited in the literature include increased operative time and associated increased costs. The authors' personal experience is that operative time is similar and in many times reduced, especially for patients with a high body mass index. However, complex operative laparoscopy is associated with a steep and lengthy learning curve after which operative time is significantly reduced based on the surgeon's experience and laparoscopy skills as well as the quality of the operative team.

A thorough knowledge of pelvic floor anatomy is essential before undertaking any type of reconstructive pelvic surgery, and advanced knowledge of laparoscopic surgery and suturing are essential to perform the surgical procedures discussed in this review. Despite the paucity in the literature, laparoscopic pelvic reconstructive surgery will continue to be driven by patient demands as well as surgeon preference. With increasing experience, greater data should support its continued use and favorable long-term outcomes.



## SUGGESTED READING:

DeLancey JO. Anatomic aspects of vaginal eversion after hysterectomy. *Am J Obstet Gynecol* 1992;166:1717-24

Richardson AC. The rectovaginal septum revisited: its relationship to rectocele and its importance in rectocele repair. *Clin Obstet Gynecol* 1993;36:976-983

Richardson AC. The anatomic defects in rectocele and enterocele. *J Pelvic Surg* 1995;1:214-221

Kaupila O, Punnonen R, Teisala K. Operative technique for the repair of posthysterectomy vaginal prolapse. *An Chir Gynaecol* 1986;75:242-244

Symmonds RE, Williams TJ, Lee RA, Webb MJ. Post-hysterectomy enterocele and vaginal vault prolapse. *Am J Obstet Gynecol* 1981;140:852-859

Cruikshank SH, Kovac SR. Anterior vaginal wall culdoplasty at vaginal hysterectomy to prevent posthysterectomy anterior vaginal wall prolapse. *Am J Obstet Gynecol* 1996;174:1863-1869

Ross JW. Apical vault repair, the cornerstone of pelvic floor reconstruction. *Int Urogynecol J* 1997;8:146-152

Ross JW. Techniques of laparoscopic repair of total vault eversion after hysterectomy. *J Am Assoc Gynecol Laparosc* 1997;4:173-183

Miklos JR, Kohli N, Lucente V, Saye WB. Site specific fascial defects in the diagnosis and surgical management of enterocele. *Am J Obstet Gynecol*. 1998;179:1418-1423

Carter JE, Winter M, MendeIshohn S, Saye WB, Richardson AC. Vaginal vault suspension and enterocele repair by Richardson-Saye laparoscopic technique: description of training technique and results. *J Soc Laparoend Surg* 2001;5:29-36

Lyons TL. Minimally invasive treatment of urinary stress incontinence and laparoscopically direct repair of pelvic floor defects. *Clin Obstet Gynecol* 1995;38:380-391

Koninckx PR, Poppe W, Depress J. Carbon dioxide laser for laparoscopic enterocele repair. *J Am Assoc Gynecol Laparosc* 1995;2:181-185

Nezhat CH, Nezhat F, Nezhat C. Laparoscopic sacral colpopexy for vaginal vault prolapse. *Obstet Gynecol* 1994;4:381-383

Lyons TL, Winer WK. Vaginal vault suspension. *Endosc Surg* 1995;3:88-92



Cosson M, Rajabally R, Bogaert E, Querleu D, Crepin G. Laparoscopic sacrocolpopexy, hysterectomy and burch colposuspension: feasibility and short-term complications of 77 procedures. *J Soc Lap Surg* 2002;6(2):115-119

Wattiez A, Canis M, Mage G, Pouly JL, Bruhat MA. Promontofixation for the treatment of prolapse. *Urol Clin N Amer* 2001;28:151-157

Rozet F, Mandron E, Arroyo C, et al. Laparoscopic sacral colpopexy approach for genitourinary prolapse: experience with 363 cases. *Eur Urol* 2005 Feb;47(2):230-6